

## Viral Disease And Gut Health in Poultry



**Dr. B C Dutta**  
Poultry Consultant &  
Author

Impact of viral diseases on gut health in poultry is mostly overlooked, because the poultry fraternity is more concerned about those viral diseases which cause heavy mortality. For gut health, industry is concerned about bacterial (Necrotic Enteritis) and protozoan (Coccidiosis) diseases, feed, nutritional issues, gut microbiota, drinking water quality, stress, etc. Several viral infections cause damage of gastro-intestinal system and are very important from the economic point of view as they result in heavy losses on account of indigestion, malabsorption

& feed passage due to clinical & subclinical infections.

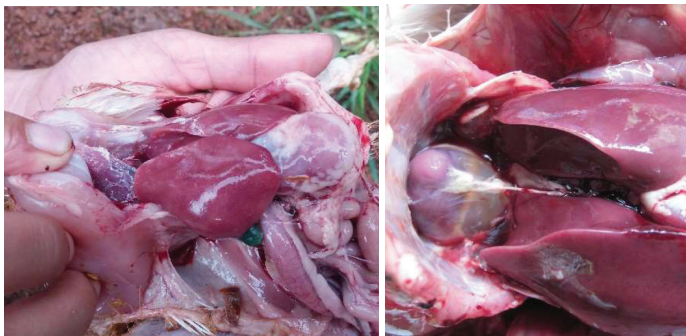Feed is the major cost in poultry and second biggest constraint to global poultry industry. Gut health is the major factor that affects feed efficiency i.e. feed cost per unit production.

Many viral infections have been associated with enteric diseases of chickens, including Coronavirus (IB), Reoviruses, Rotaviruses, Adenoviruses, Enteroviruses, Chicken Astrovirus and Avian Nephritis Virus (ANV) in addition to other highly pathogenic diseases like LPAI (Bird Flu), ND and Gumboro (IBD) which are basically not enteric diseases but affect gut health.

The clinical signs of enteric disease in poultry are infrequent or occur independently of previous conditions, such as the presence of primary or secondary etiological agents, the immune and nutritional status of the bird, and environmental conditions. Out of various signs of enteric disease, diarrhoea and lack of normal growth & reduced production are the most consistent symptoms.

### Adenovirus Infections

Inclusion Body Hepatitis (IBH) & Hydropericardium Syndrome (HPS) are caused by Adenovirus in chicken, mostly in meat

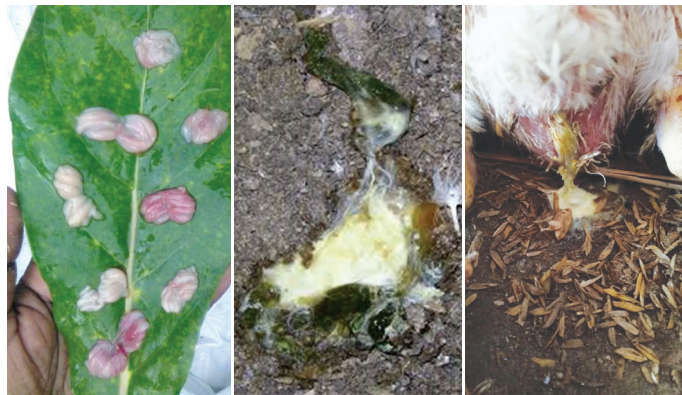

type birds and damage of intestinal mucosa is a common post mortem lesion. In IBH, the liver is greatly damaged leading to reduced bile production and repressed fat digestion in chicken.

Adenovirus can be seen 8<sup>th</sup> day age onwards in broilers when mortality is usually slow, @ 0.3 – 0.7% daily but loose droppings with undigested feed (Feed Passage) and wet litter are common signs. On post mortem, the liver shows pathognomic fatty liver condition, distended intestine and kidney haemorrhages; sometimes with urate crystals. The damage of intestinal mucosa invites many more enteric infections like Clostridium, Staphylococcus, Coccidiosis, etc.

### Infectious Bursal Disease

IBD or Gumboro disease is the most important and highly contagious viral disease of poultry. While the acute form is very common, the subclinical form is becoming a global menace. The disease is a major problem in concentrated poultry production areas throughout the world. It is often not recognized due to a sub-clinical form. Affected chickens have increased vaccine



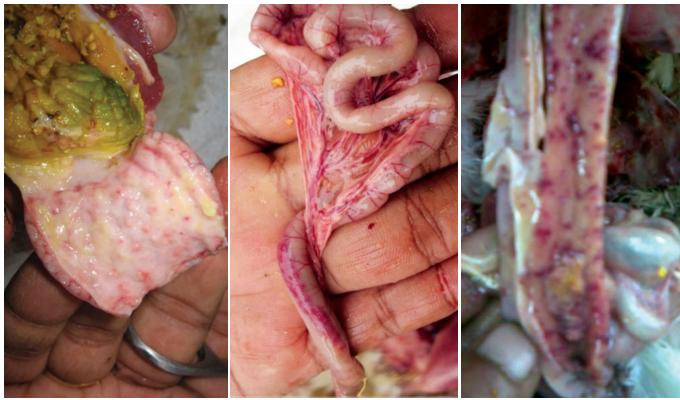
failure, strong post-vaccinal reactions, & increased incidence of secondary infections.

Watery droppings is one of the first symptoms of IBD due to damage of intestinal mucous membrane and white chalky diarrhoea is a common sign of Gumboro. Digestion & absorption of nutrients are usually severely impacted and the birds get dehydrated with loss of body weight. Gumboro disease affects the GALT which is directly related to gut health by increasing permeability of intestinal mucosa and by facilitating 'leaky gut syndrome'.

### Newcastle Disease (ND)

Newcastle Disease (ND) is one of the important viral diseases of birds that causes devastating economic losses in the global poultry industry with very high mortality involving respiratory, nervous & digestive system dysfunctions. Out of 5 different pathogenic virus classes, the most harmful & least harmful virus cause GIT disorders.

ND infection induces interferon production, which increases the lethality of bacterial endotoxin (LPS) and causes the dispro-

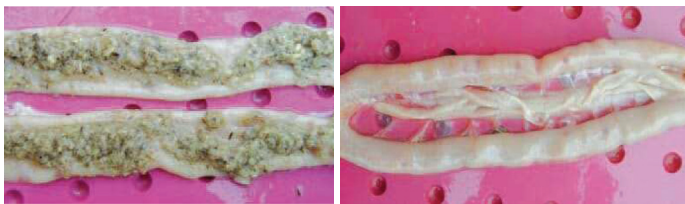

portion of intestinal microbiota in chickens. Experiments have proved that ND infection interferes with the formation of GIT microbial population in newly hatched chicks. Damage of intestinal epithelium, green diarrhoea (mixed with excess bile in duodenum) & dehydration are common signs

#### Reovirus Infection or Malabsorption Syndrome

Avian reoviruses are frequently detected in the intestinal tracts of poultry with enteric disease which causes malabsorption/maldigestion/pale bird syndrome.

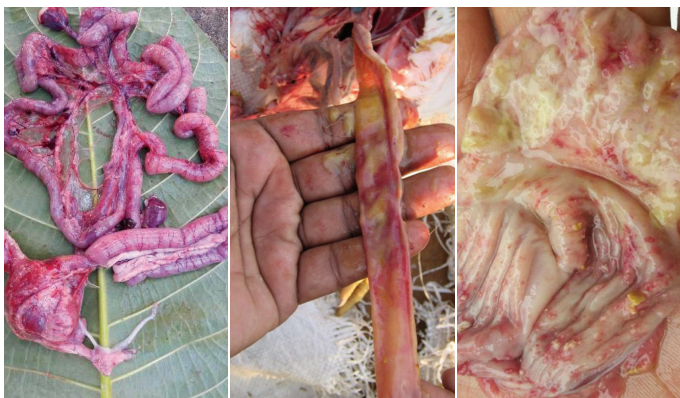Affected birds are stunted, unthrifty, have poor feed conver-



sions and generally look dull. Various degrees of diarrhoea (orange tinged) and maldigestion are the main signs. Usually, a high-degree atrophy of the pancreas is observed. Mortality is usually low although morbidity is high. This condition is usually seen between 3-6 weeks of age and is usually observed in meat type chickens.

#### LPAI or Bird Flu

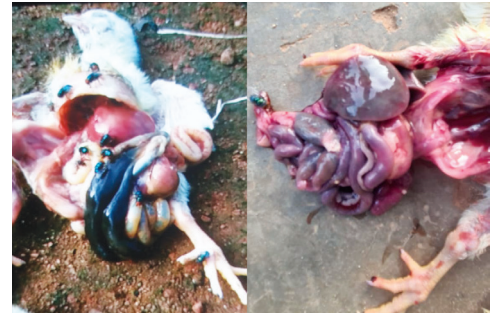Avian Influenza is a fatal viral disease of wild & domestic birds including chickens characterized by extremely high mortality, globally. In LPAI, viral replication and shedding occurs within the



intestinal mucosa; resulting in heavy damage and destruction of gut epithelium. Gizzard erosion is extreme, resulting in almost non-functional gizzard and impaired GIT function with greenish white diarrhoea.

#### Avian Rotavirus

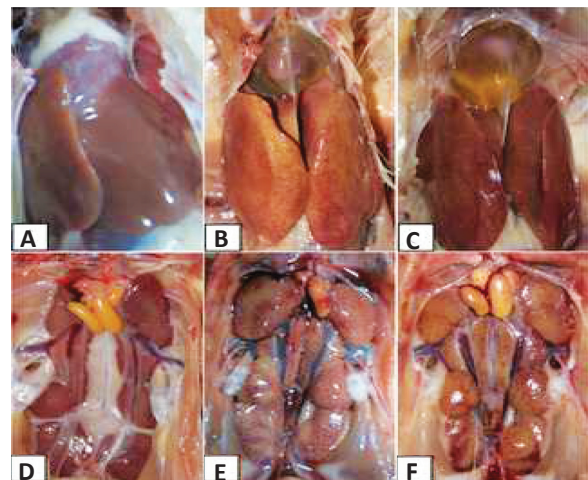
Avian Rotavirus infection is confined to the GIT and grows mainly in the mature epithelial cells of small intestine. The destroyed epithelial cells result in reduced digestive capacity, leading to more carbohydrate & protein in hind gut causing frothiness in caeca which may favour the growth of Clostridium for secondary infection of Necrotic Enteritis. Rotavirus infections are mainly seen in the first 5 weeks of age but may appear at any age.



In broilers, symptoms vary from subclinical infections to outbreaks of diarrhoea with dehydration, litter eating, vent pecking, poor weight gain, high morbidity and increased mortality. Post mortem reveals abnormal amount of fluid & gas in the intestinal tract & caeca, inflamed vent and litter in the gizzard.

#### Avian Astrovirus

Chicken Astrovirus (CAstV) has been associated with poor growth of broiler flocks, enteritis and diarrhoea and produces runting stunting syndrome. Avian astroviruses are highly prevalent endemic viruses, globally infecting diverse avian species, mainly young birds.



Although mainly enteric infections, all astroviruses can be detected in other organs as well. Post mortem lesions include multiple microscopic lesions in the intestinal wall filled with necrotic cells and mucin. Atrophy of villi and altered crypt depth or mild crypt hyperplasia may be observed, especially in the jejunum. These infections can also result in mild to moderate atrophy of the bursa and thymus resulting immunosuppression. In chick nephritis, kidney lesions and widespread urate deposits on the viscera may be apparent.

**Treatment & control of viral infections affecting gut health is the standard process of viral disease control with :**

- Implementation of 100% biosecurity norms
- Maintenance of farm hygiene
- Health maintenance so that the birds can protect themselves from viral infections
- Scientific vaccination for all viral diseases that have available vaccines